



DATE PRESENTING CLINICAL SIGNS
History: Murmur.

1/5/22

ECHOCARDIOGRAPHIC FINDINGS

PERFORMED BY: 2D, M-mode, and Doppler study.

Potomac Mobile
Veterinary
Ultrasound

Left atrial size is normal. The mitral valve leaflets are mildly thickened, and there is Doppler evidence of mitral regurgitation present. Left ventricular dimensions are normal. Left ventricular systolic function is mildly hyperdynamic. The aorta and aortic valve are normal. There is mild right atrial and right ventricular dilation. The tricuspid valve leaflets are thickened, and there is Doppler evidence of tricuspid regurgitation present. TR velocity is consistent with the presence of moderate pulmonary hypertension (PG 56 mmHg). The pulmonary artery and pulmonic valve are normal. No shunting lesions are visualized. No pericardial effusion or cardiac masses are seen.

INTERPRETED BY

Keith Blass, DVM,
MS, DACVIM
(Cardiology)

LA - 16.3 mm
LVIDd - 16.8 mm
LVIDs - 9.7 mm
FS - 42%
RA - 19.4 mm
LVOT - 1.02 m/s
RVOT - 0.72 m/s
TR - 3.74 m/s

PATIENT

Peanut Babb

SPECIES

Canine

ASSESSMENT/RECOMMENDATIONS

Degenerative mitral and tricuspid valve disease
Pulmonary hypertension

BREED

Chihuahua

This examination demonstrates regurgitation of blood across Peanut's mitral and tricuspid valves resulting from degenerative valve disease. Peanut's mitral valve disease is mild, and appears to be well-compensated at this time. His tricuspid valve disease is a bit more advanced, as Peanut has mild secondary dilation of both his right atrium and right ventricle. In addition, Peanut's TR velocity is consistent with the presence of moderate pulmonary hypertension. Given these findings, Peanut is at risk for the development of right-sided congestive heart failure, as well as exercise intolerance and syncope, therefore, careful monitoring for these is recommended.

SEX

MN

Recommended therapy based on this exam includes pimobendan (1.25 mg am, 0.625 mg pm) and sildenafil (5 mg BID).

AGE

A recheck echocardiogram is recommended in 6 months.

6 y

WEIGHT

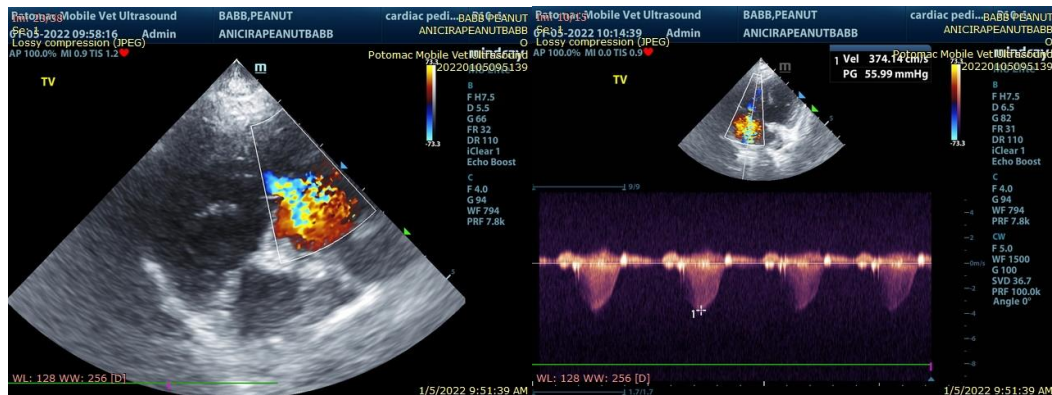
6.8 lb

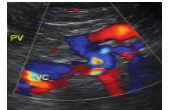
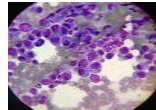
HOSPITAL NAME

Aniciria Vet Center

REFERRING VET

Dr. Jarrett





DATE

1/5/22

The information and recommendations provided are based on the images presented by the referring veterinarian. No evaluation can be communicated regarding pathology that was not visible in the image/video clips provided.

PERFORMED BY:

Thank you for this referral. If the clinical or image interpretation does not parallel your findings or if I can be of any further assistance please contact me.

Potomac Mobile
Veterinary
Ultrasound

Keith Blass, DVM, MS, DACVIM (Cardiology)
KeithBlass@gmail.com
631-804-5754

INTERPRETED BY

Keith Blass, DVM,
MS, DACVIM
(Cardiology)

PATIENT

Peanut Babb

SPECIES

Canine

BREED

Chihuahua

SEX

MN

AGE

6 y

WEIGHT

6.8 lb

HOSPITAL NAME

Aniciria Vet Center

REFERRING VET

Dr. Jarrett